

Timothy Wong, DO, Stephen M. Scheinthal DO, DFACN, DFAPA, CS  
Rowan University School of Osteopathic Medicine, Stratford, New Jersey

## SIGNIFICANCE

Delusional infestation (DI) is a somatic-type delusional disorder, characterized by a fixed belief that one is infested by living or nonliving pathogens.<sup>1</sup> DI is rare, with only 20-80 cases per million people annually,<sup>2</sup> and patients are hardly ever seen in psychiatry as they preferably seek other specialists such as dermatologists.<sup>3,4</sup> Effective management is crucial as patients may cause significant harm to themselves in their attempts to remove the pathogens.<sup>4,5</sup> To that end, treatment with antipsychotic medications such as pimozide and risperidone have been promising.<sup>5-7</sup> It is crucial for consultation-liaison psychiatrists to effectively evaluate and treat DI when the opportunities arise.

## CASE PRESENTATION

Our patient is a 45-year-old male with a history of paraplegia, admitted to the hospital for sepsis secondary to lower extremity wounds and decubitus ulcers. He required amputation of his left leg and improved medically thereafter. Psychiatry was consulted for delusions. Over our evaluation, it was revealed that patient developed DI 6-7 months prior to this admission. It started with “cotton threads” in his fingernails and progressed to “bugs” on his extremities, eyes, and tongue. The patient attributed his symptoms to Morgellons, Lyme disease, and fungal infection. He has taken photos of the “bugs”, but family denied any findings in the pictures. He has been scratching himself with a knife at times and was even seen washing himself extensively with caustic chemicals such as bleach and sodium tetraborate soap.

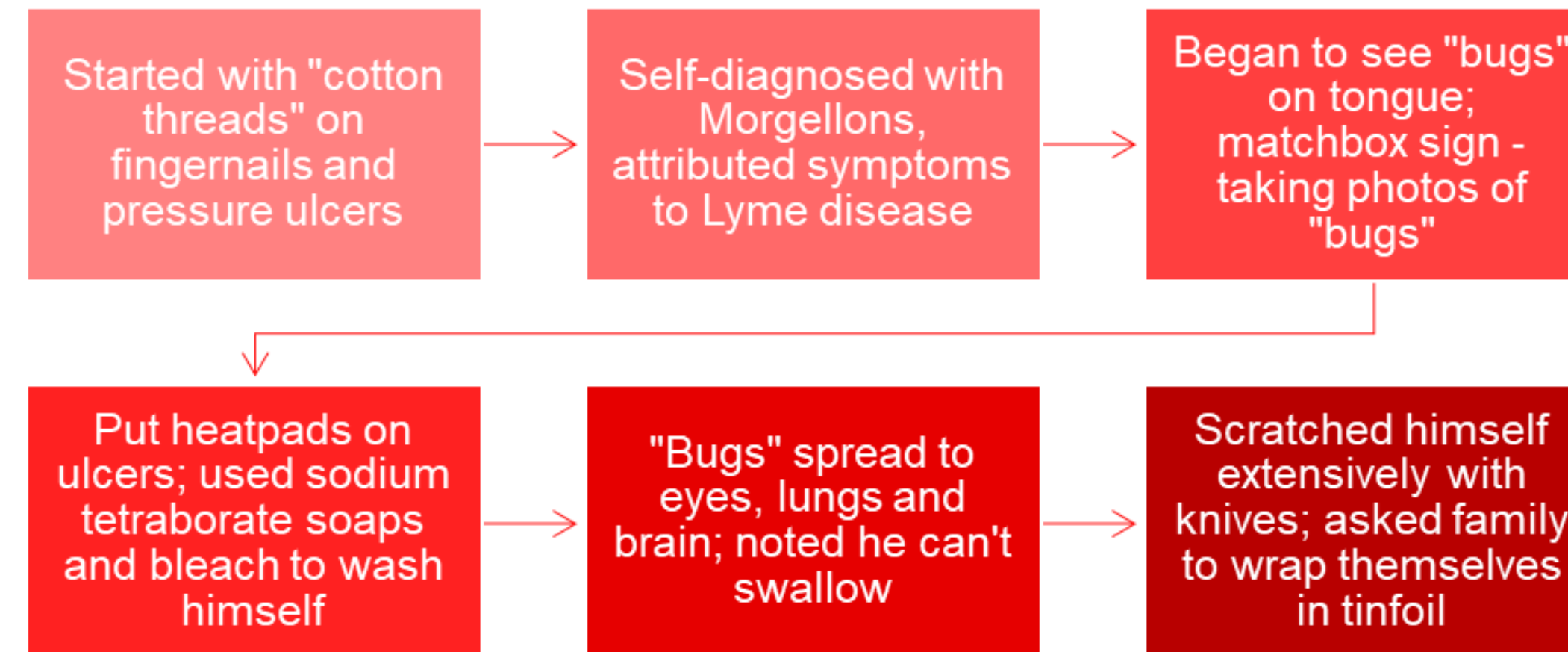


Figure 1 - Progression of patient's symptomatology and key features

During this hospitalization, the patient was started on risperidone 0.5mg daily and titrated up to 1mg BID with good tolerance. After 4 days, he no longer complained of itching. While he maintained that he was still infested, the pathogens are “dormant” at this time. The patient was discharged to rehabilitation facility shortly after.

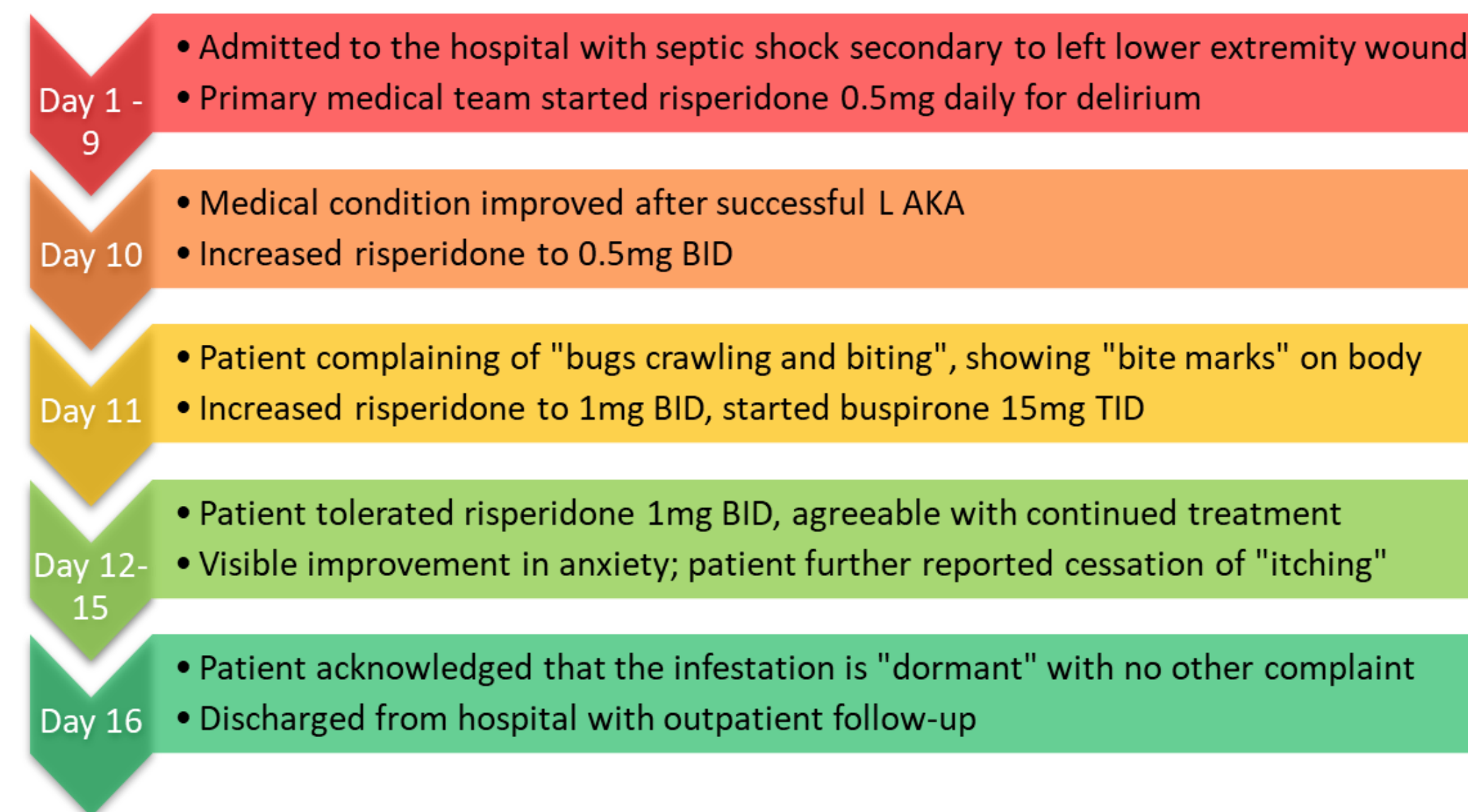


Figure 2 - Timeline of patient's hospitalization

## DISCUSSION

We reported here on a patient with primary delusional infestation. This case illustrates the significant medical complications that may result from DI and further highlights the need for treatment. Risperidone has shown efficacy in limited studies, with a positive impact rate of 69%.<sup>5</sup> Our patient showed early promise through treatment with risperidone, with the remission of tactile hallucinations and the acknowledgement that the pathogens may be “dormant”. Establishment of a trusting patient-physician relationship is particularly crucial in the treatment of DI, and we are optimistic that this patient is on the proper path to recovery.

## CONCLUSION

Delusional infestation is a rare and potentially devastating disorder. It is crucial for consultation-liaison psychiatrists to understand the treatment barriers inherent with this delusional disorder, and when the opportunities arise, properly manage and treat patients with delusional infestation.

## REFERENCES

- Bewley, A. P., Lepping, P., Freudenmann, R. W., & Taylor, R. (2010). Delusional parasitosis: time to call it delusional infestation. *The British journal of dermatology*, 163(1), 1–2.
- Moriarty, N., Alam, M., Kalus, A., & O'Connor, K. (2019). Current Understanding and Approach to Delusional Infestation. *The American journal of medicine*, 132(12), 1401–1409.
- McPhie, M. L., & Kirchof, M. G. (2020). A systematic review of antipsychotic agents for primary delusional infestation. *The Journal of dermatological treatment*, 1–13. Advance online publication. <https://doi.org/10.1080/09546634.2020.1795061>
- Meraj, A., Din, A. U., Larsen, L., & Liskow, B. I. (2011). Self inflicted corneal abrasions due to delusional parasitosis. *BMJ case reports*, 2011, bcr0420114106.
- Reich, A., Kwiatkowska, D., & Pacan, P. (2019). Delusions of Parasitosis: An Update. *Dermatology and therapy*, 9(4), 631–638.
- Campbell, E. H., Elston, D. M., Hawthorne, J. D., & Beckert, D. R. (2019). Diagnosis and management of delusional parasitosis. *Journal of the American Academy of Dermatology*, 80(5), 1428–1434.
- Ochiai, S., Sugawara, H., Kajio, Y., Tanaka, H., Ishikawa, T., Fukuhara, R., Jono, T., & Hashimoto, M. (2019). Delusional parasitosis in dementia with Lewy bodies: a case report. *Annals of general psychiatry*, 18, 29.

Eposter:

<https://42bc4161a075f7e50e6f-a3bc3137033c5da42be80ce1198f9076.ssl.cf1.rackcdn.com//1776693-1634484015.pdf>

DOI: <https://doi.org/10.1016/j.jaclp.2022.03.059>

Original: <https://www.eventscribe.net/2021/CLP2021/index.asp?posterTarget=428267>

**PO-054**

## **(PO-054) (PO-054) Evaluation and Treatment of Primary Delusional Infestation in a Hospitalized Patient with Paraplegia: A Case Report**

Presented at CLP 2021, the annual meeting of the Academy of Consultation-Liaison Psychiatry

### **Significance:**

Delusional infestation (DI) is a somatic-type delusional disorder, characterized by a fixed belief that one is infested by living or nonliving pathogens. DI is very rare, and patients are hardly ever seen in psychiatry as they preferably seek other specialists such as dermatologists (McPhie, 2020). Patients may cause significant harm to themselves in their attempts to remove the pathogens (Reich, 2019). It is crucial for consultation-liaison psychiatrists to effectively evaluate and treat DI when the opportunities arise.

### **Case Summary:**

Our patient is a 45-year-old male with a history of paraplegia, admitted to the hospital for sepsis secondary to lower extremity wounds and decubitus ulcers. He required amputation of his left leg and improved medically thereafter. Psychiatry was consulted for delusions. Over our evaluation, it was revealed that patient developed DI 6-7 months prior to this admission. It started with “cotton threads” in his fingernails and progressed to “bugs” on his extremities, eyes, and tongue. The patient attributed his symptoms to Morgellons, Lyme disease, and fungal infection. He has taken photos of the “bugs”, but family denied any findings in the pictures. He has been scratching himself with a knife at

times and was even seen washing himself extensively with caustic chemicals such as bleach and sodium tetraborate soap. During this hospitalization, the patient was started on risperidone 0.5mg daily and titrated up to 1mg BID with good tolerance. After 4 days, he no longer complained of itching. While he maintained that he was still infested, the pathogens are “dormant” at this time. The patient was discharged to rehabilitation facility shortly after.

### **Discussion:**

We reported here on a patient with primary delusional infestation. This case illustrates the significant medical complications that may result from DI and further highlights the need for treatment. Risperidone has shown efficacy in limited studies, with a positive impact rate of 69% (Reich, 2019). Our patient showed early promise through treatment with risperidone, with the remission of tactile hallucinations and the acknowledgement that the pathogens may be “dormant”. Establishment of a trusting patient-physician relationship is particularly crucial in the treatment of DI, and we are optimistic that this patient is on the proper path to recovery.

### **Conclusion:**

Delusional infestation is a rare and potentially devastating disorder. It is crucial for consultation-liaison psychiatrists to understand the treatment barriers inherent with this delusional disorder, and when the opportunities arise, properly manage and treat patients with delusional infestation.

### **References:**

McPhie, M. L., & Kirchhof, M. G. (2020). A systematic review of antipsychotic agents for primary delusional infestation. *The Journal of dermatological treatment*, 1–13. Advance online publication. <https://doi.org/10.1080/09546634.2020.1795061>

Reich, A., Kwiatkowska, D., & Pacan, P. (2019). Delusions of Parasitosis: An Update. *Dermatology and therapy*, 9(4),631–638.

## Learning Objectives:

- To describe a case of delusion infestation.
- To recognize common symptoms and treatment options of delusion infestation.
- To discuss evaluation and management of delusion infestation in the hospital setting.

## Presenting Author(s)

**Timothy Wong, DO** – Psychiatry Resident, Rowan University School of Osteopathic Medicine, Philadelphia, PA, United States

## Co-Author(s)

**Stephen Scheinthal, DO, DFACN, DFAPA, CS** – Professor and Chair, Rowan University School of Osteopathic Medicine, Department of Psychiatry, Mt. Laurel, NJ, United States